



Secondary Spontaneous Pneumothorax in Former Pulmonary Tuberculosis: a Case Report

Syamsu Rijal¹, Windy Nurul Aisyah², Bulkis Natsir³, Julian Muhammad Yasin⁴

¹Department of Anatomical Pathology, Faculty of Medicine, Indonesian Muslim University

²Department of Parasitology, Faculty of Medicine, Indonesian Muslim University

³Department of Pulmonology, Faculty of Medicine, Indonesian Muslim University

⁴Students of Medical Professional Study Program, Faculty of Medicine, Indonesian Muslim University

*Corresponding Author: Syamsu Rijal

E-mail: syamsu.rijal@umi.ac.id



Article Info

Article history:

Received 18 April 2024

Received in revised form 7

May 2024

Accepted 18 May 2024

Keywords:

Pneumothorax

Secondary Spontaneous

Pneumothorax

Pulmonary Tuberculosis

Abstract

A 36-year-old male presented to the hospital with a chief symptom of dyspnea that began one day before admission and increased during the night upon admission. The individual does not experience nausea, vomiting, heartburn, and has regular urination and normal bowel movements. Loss of appetite and fatigue. There is no prior record of comparable grievances. The existence of a history of trauma cannot be refuted. Past medical history: The patient had pulmonary TB and completed treatment in April 2023. During the physical examination, the patient's overall condition was observed to be moderately unwell, with a clear and alert state of consciousness. Assessment of vital signs revealed a blood pressure of 117/84 mmHg, a pulse rate of 65 beats per minute, a respiratory rate of 25 breaths per minute, a body temperature of 37°C, and an oxygen saturation level of 94%. In the thoracic region, the examination reveals the following findings: - Inspection shows movement of the chest wall on the left side. - Palpation detects weakened tactile fremitus on the left side. - Percussion produces a hypersonor sound on the left side. - Auscultation reveals normal vesicular sounds on the right side and weak vesicular sounds on the left side. Rhonchi are not present, but wheezing is heard in both sides of the chest. The supporting studies yielded a complete blood count within normal range, a VCT examination showing non-reactive HIV antibodies, a TCM sputum examination with undetectable MTB findings, and a chest X-ray examination indicating left pneumothorax and active pulmonary TB.

Introduction

Pneumothorax is a medical disorder characterized by the presence of air in the pleural cavity, resulting in increased pressure in the lungs and impaired lung expansion. Pneumothorax is divided into traumatic and non-traumatic (spontaneous) pneumothorax based on the cause. Spontaneous pneumothorax is categorized into primary spontaneous pneumothorax (PSP), which occurs in individuals with no prior history of lung disease, and secondary spontaneous pneumothorax (PSS), which occurs in individuals with a previous history of lung disease. Pneumothorax is categorized according to the type of fistula, which includes closed pneumothorax, open pneumothorax and ventil pneumothorax (Amanda & Wijayanti, 2015; Setiati et al., 2014).

Pulmonary tuberculosis (TB) is a common lung disease associated with PSS. The prevalence of PSS due to pulmonary tuberculosis is currently quite low, with provisional global estimates

ranging from 0.6% to 1.4% of cases. The incidence rate of Progressive Supranuclear Palsy (PSP) in the United States is 7.4 cases per 100,000 people per year in men and 1.2 cases per 100,000 people annually in women. Currently, the reported incidence of PSS patients is 6.3 cases per 100,000 people in men and 2 cases per 100,000 people in women. In Indonesia, the incidence of pneumothorax is between 2.4 and 17.8 cases per 100,000 people per year. Between 2000 and 2011, Cipto Mangunkusumo Hospital treated a total of 104 people with pneumothorax, with primary spontaneous pneumothorax as many as 26 patients (25%), secondary spontaneous pneumothorax as many as 49 patients (47.1%), traumatic pneumothorax as many as 14 patients (13.5%) and tension pneumothorax as many as 15 patients (14.4%). The mortality aspect of smoking was 43 patients (41.3%), pneumonia as many as 42 patients (40.3%), and tuberculosis as many as 37 patients (35.5%). The most common type of pneumothorax was secondary spontaneous pneumothorax in 49 patients (47.1%) (Masengi et al., 2016; Jayanti, 2018).

Pneumothorax can appear when air infiltrates the pleural cavity, either due to injury to the chest wall or injury to the lung itself. Spontaneous pneumothorax occurs due to the rupture of a bleb or bullae. Pneumothorax is one of the complications that can arise in individuals who have tuberculosis. This scenario arises with the occurrence of secondary pneumothorax, when a nearby cavity ruptures, then inspired air enters the pleural cavity. One rare factor is bronchopleural fistula, which allows the infection to pass from the interstitial tissue as well as the bronchi to the subpleura (Setiati et al., 2014; Simamora & Rashidah 2020; Putri & Kaniya, 2019).

A 36-year-old man came to the hospital with the main symptoms of dyspnea that began one day before admission and increased in the evening after admission. Dyspnea worsens during activity, but improves when activity is stopped. Additional complaints include the absence of fever, the absence of headaches, the absence of productive cough, and the presence of chest pain when coughing. The individual does not experience nausea, vomiting, heartburn or normal urination and bowel movements. Experiencing reduced desire to eat and sensations of physical weakness. There is no record of similar complaints before. The existence of a history of trauma is undeniable. Past medical history: Successful completion of pulmonary tuberculosis treatment by April 2023.

During the general physical examination, the individual is judged to be unhealthy, with mental abilities and consciousness intact. Vital signs assessment obtained the following results: blood pressure 117/84 mmHg, pulse rate 65 times per minute, respiratory frequency 25 times per minute, body temperature 37°C, and oxygen saturation 94%. In the thoracic region, the examination shows the movement of the left chest wall. Palpation indicates a weakening of the sense of touch on the left side of the chest. Percussion produces a loud sound in the left chest. Auscultation shows normal vesicular sounds in the right chest, but weak sounds in the left chest. There is no abnormal ronki sound, but there is wheezing on both sides of the chest. The heart seems to function normally. On physical examination of the head, neck, stomach and limbs no abnormalities were found.

Laboratory and radiographic examinations are performed. Laboratory analysis showed that the total blood count was within the normal range, the VCT test for HIV antibodies was negative, and the TCM sputum test showed no MTB was detected. Radiological examination obtained thoracic photos on July 27, 2023 with the results of the examination appearing *avasascular hiperlusen* on the left hemithorax that gives an overview *pleural white line* which slightly urges the heart, and appears infiltrate spots in the upper zone of the right lung and left paracardial accompanied by minimal fibrotics in the upper zone of the right lung, with the impression of pneumothoraks sinistra and active long-active pulmonary TB. Thoracic photo examination on July 31, 2023 after installation *water-sealed drainage* (WSD), obtained bronchovascular smear illustrations of both prominent lungs accompanied by fibrosis, and the end of the chest tube

ICS 6-7 left back, with the impression of invisible pneumothoraks, the end of the chest tube in ICS 6-7 left back, and fibrosis of both lung suspected of old TB.

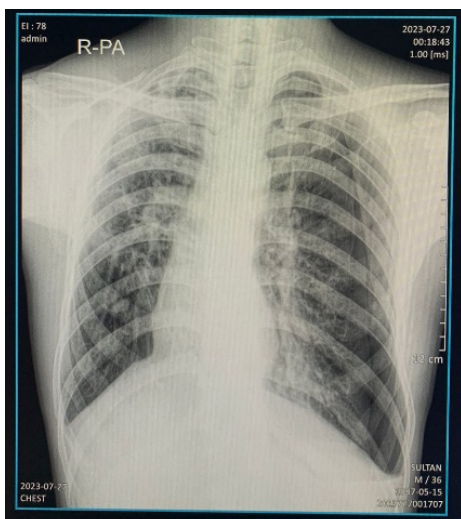


Figure 1. Photograph of a patient's thorax with PA projection prior to WSD insertion

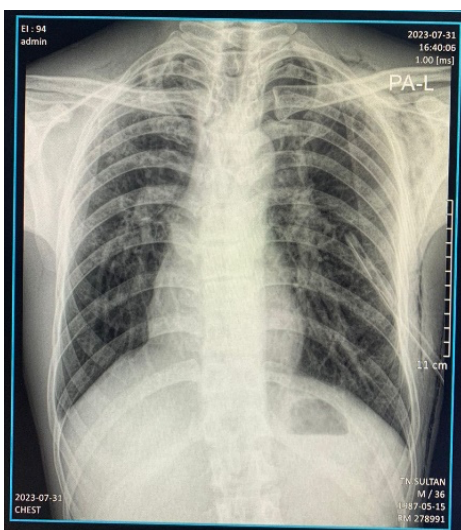


Figure 2. Thoracic photograph of a patient with PA projection after WSD insertion

From the anamnesis, physical examination and supporting examinations, the patient's clinical diagnosis is spontaneous pneumothoraks sinistra in former pulmonary TB. Patients are hospitalized for 8 days and given treatment, namely the installation of *water-sealed drainage* (WSD), Oxygen 3 liters / minute, IVFD RL 28 drops / minute, Biocombin 1 amp / 24 hours / drips, Ranitidine 50 mg / 12 hours / IV, Ketorolac 30 mg / 8 hours / IV, Dexamethasone 1 amp / 12 hours / IV, Ampicillin Sulbactam 1.5 g / 12 hours / IV, Nebu Combivent resp / 24 hours / inhalation, Nebu Pulmicort resp/24 hours/inhalation, Cefadroxil 500 mg 2x1 tab, Ambroxol 30 mg 3x1 tab, Mefenamic Acid 500 mg 2x1 tab.

Methods

The study is a case report involving medical review and single-case analysis. The study subject was a 36-year-old man who came to the hospital with the main symptoms of dyspnea that began one day before hospital admission and increased in the evening after admission. Data is collected through the patient's history, physical examination, and diagnostic test results, including thoracic photographs and thoracic CT scans. The collected data is analyzed to describe the patient's clinical presentation, including symptoms, physical findings, and diagnostic test results. The analysis also includes patient care and treatment journey. The

management approach consists of initial management and treatment course. Initial management includes emergency measures such as the insertion of a chest catheter for air evacuation and patient observation. The course of treatment includes evaluation of the patient's response to initial measures, monitoring of symptoms, and the need for additional measures. The study was conducted with due regard to the ethical principles of the study, including maintaining the confidentiality of patient information and obtaining written permission prior to publication.

Result and Discussion

Pneumothorax refers to the accumulation of air inside the pleural cavity. Pneumothorax can be classified namely; spontaneous, which occurs in the absence of trauma or trauma, which is the result of direct or indirect chest trauma. Spontaneous pneumothorax can be classified into two types: primary spontaneous pneumothorax (PSP) and secondary spontaneous pneumothorax (PSS). PSP occurs in individuals who are healthy and have no previous lung disease. On the other hand, PSS is a pre-existing complication of lung disease in patients (Andres Giraldo Vallejo et al., 2019; Franco et al., 2019).

Pulmonary tuberculosis (TB) is a common lung disease that often underlies PSS. The prevalence of PSS due to pulmonary tuberculosis is currently quite low, with provisional estimates ranging from 0.6% to 1.4% of cases. Internationally, the prevalence of PSP in the United States is 7.4 cases per 100,000 people per year in men and 1.2 cases per 100,000 people per year in women. While the incidence of PSS cases is 6.3 cases per 100,000 people in men and 2 cases per 100,000 people in women. The prevalence of PSP in the UK is 16.8 cases per 100,000 people annually. The incidence of spontaneous pneumothorax in Sweden is 18 cases per 100,000 people per year in men and 6 cases per 100,000 people per year in women (Huan et al., 2021; Karmakar, 2022).

In Indonesia, the incidence rate of pneumothorax ranges from 2.4 to 17.8 cases per 100,000 people per year. Between January 2000 and December 2011, a total of 215 pneumothorax patients were treated at Cipto Mangunkusumo Hospital. A comprehensive set of medical records was collected and examined for a total of 104 patients. The study subjects consisted of 78 men (73.1%) and 26 women (26.9%), with a gender ratio of 3:1. The average age of participants in the study was 39.7 years, ranging from 17 years as the youngest to 81 years as the oldest. In the study, patients with primary spontaneous pneumothorax were 26 patients (25%), secondary spontaneous pneumothorax as many as 49 patients (47.1%), traumatic pneumothorax as many as 14 patients (13.5%) and tension pneumothorax as many as 15 patients (14.4%). The most respiratory complaints were shortness of breath as many as 103 patients (99%) and abnormalities in physical examination in the form of hyperpersonors as many as 101 patients (97.1%). Plain thoracic photographs showed avascular hysicene in 95 patients (91.4%). The highest incidence of smoking was 43 patients (41.3%), pneumonia as many as 42 patients (40.3%), and tuberculosis as many as 37 patients (35.5%). The most common type of pneumothorax was secondary spontaneous pneumothoraks in 49 patients (47.1%). Most of the cases were treated with the installation of *water-sealed drainage* (WSD), which was 98 patients (94.2%). The output of live pneumothoraks patients was 69 patients (66.3%). The mortality rate was quite high as many as 35 patients (33.7%), with the most causes of death respiratory failure amounting to 16 patients (45.8%) (Jayanti, 2018).

Epidemiological data show that the highest incidence of pneumothoraks is secondary spontaneous pneumothoraks, where spontaneous pneumothoraks are more common in men than women. Aspects that worsen survival include smoking, pneumonia, pulmonary TB, chest trauma, lung malignancy, and COPD. The mortality of pneumothoraks is generally related to respiratory failure. In line with secondary spontaneous pneumothoraks in former pulmonary TB that occur in males. The main complaint of patients upon admission is acute dyspnea, which

initially appears one day earlier and worsens at night. Shortness of breath worsens on exertion but subsides at rest, without any previous physical injury.

During the physical examination of the patient, the following observations are made in the thoracic region: - On examination found movement of the chest wall on the left side, both statically and dynamically. Palpation indicates a decrease in tactile fremitus in the left half of the chest. Percussion in the left half of the chest produces a higher-pitched sound (hyperpersonor). In auscultation, vesicular sounds are heard in the right hemithorax, while faint vesicular sounds are heard in the left hemithorax. There was no ronki, but there was wheezing on both hemithorax. The findings of the patient's physical examination are in line with the literature, indicating the presence of a pneumothorax during the evaluation. Upon examination, there is a decrease in chest wall movement on the affected side. Thoracic percussion shows hyperpersonor sound indicating an increase in air volume in the thoracic region. Palpation indicates a decrease in tactile fremitus, and auscultation indicates a decrease in breath sounds on the affected side (Setiati et al., 2014).

Lung disorders commonly associated with pneumothorax include COPD, cystic fibrosis, primary lung cancer, metastasis, and pneumonia, with COPD being the most common. Pneumothorax can occur in cases of cavitary TB. Among patients receiving tuberculosis treatment, pneumothorax is detected in approximately 1% to 3% of cases.¹ Such patients have previous medical conditions, particularly pulmonary tuberculosis, and have completed prescribed therapy by April 2023. Anamnesis data revealed that the main complaint was dyspnea that arose suddenly, without a history of trauma. This complaint is also considered to be increasing. According to research, if a person complains of sudden difficulty breathing and also shows symptoms of active tuberculosis, it is important to evaluate the possibility of him or her suffering from secondary spontaneous pneumothorax (PSS) (Singh et al., 2014).

In general, all forms of pneumothorax have a similar pathophysiological basis. Spontaneous pneumothorax arises due to weakening of the alveoli and visceral pleural walls. In case of rupture of the fragile walls of the alveoli and visceral pleura, fistulas can form, which leads to the ingress of air into the pleural cavity. During inhalation, the chest cavity expands, causing expansion of the pleural cavity. This expansion forces the lungs to expand, similar to a balloon being pulled inward. The expansion of the lungs produces negative intraalveolar pressure, thus allowing outside air to enter. Spontaneous pneumothorax occurs when the lungs collapse and inhaled air exits into the pleural cavity, causing intrapleural pressure to become non-negative (Guyton & Hall, 2007; Daley, 2024).

The exact process of how pulmonary tuberculosis (TB) can cause pneumothorax is still not known with certainty. However, it usually occurs in very severe cases and appears suddenly. Tuberculosis (TB) bacteria that enter the respiratory tract will settle in the lung tissue and form a cluster or focus of Ghon. Increased oxygenation in the lungs encourages TB bacteria to adapt to the aerobic environment and choose areas with higher oxygen levels. Ghon's focus will expand, resulting in damage to surrounding tissue and the formation of cavities due to caseous necrosis. Increased pressure inside the lungs' air sacs, such as when coughing, can cause the rupture of caseous necrosis tissue (cavities) into an area around the lungs called the pleural cavity. This can lead to secondary spontaneous pneumothorax (PSS) (Tschopp et al., 2015).

The diagnosis in this case was made based on the results of a chest X-ray taken from the PA projection. X-rays showed a lack of blood supply and increased transparency in the left side of the chest, resulting in a white line on the pleura that puts little pressure on the heart. In addition, there are patches of infection in the upper area of the right lung and left paracardial area, as well as minimal scarring in the upper area of the right lung. As a result, the patient was found to have left pneumothorax and long-term active pulmonary tuberculosis. A meta-analysis conducted by Ali Hebrahimi and colleagues showed that thoracic ultrasound has superior

diagnostic accuracy compared to normal chest radiography to detect the presence of pneumothorax. However, chest ultrasonography was not performed on these patients because there was previously a pneumothorax on conventional chest radiography (Ebrahimi et al., 2014).

After reviewing the patient's medical history, conducting a physical examination or other examinations, it can be determined that the patient's clinical diagnosis is a left secondary spontaneous pneumothorax due to previous cases of pulmonary tuberculosis. Treatment options for spontaneous pneumothorax include conservative therapy, oxygen therapy, simple aspiration, and intercostal catheter insertion. The approach to spontaneous pneumothorax management depends on the extent of the pneumothorax as well as the clinical status of the patient (Ebrahimi et al., 2014; Tschopp et al., 2015).

Treatment is not always necessary for small-sized spontaneous pneumothorax, as it rarely causes respiratory failure and usually resolves on its own. This method is used when the size of the pneumothorax is minimal, there is no difficulty breathing, and lung disease is not diagnosed. 24-hour monitoring can be done, and treatment options can be changed if the patient's condition worsens. Serial chest radiographs are needed to show progress. Conservative management is only suitable for cases of secondary pneumothorax that are very small (less than 1 cm) and show few symptoms. In the case of mild spontaneous pneumothorax (<15%), observation can be carried out in conjunction with 100% oxygen therapy to increase reabsorption up to fourfold (Ebrahimi et al., 2014; Tschopp et al., 2015).

Aspiration is indicated for large spontaneous pneumothorax (>15%) or symptoms of shortness of breath. Intravenous cannula is preferred over manual needles to minimize the risk of lung lacerations. The efficacy of aspiration can be observed on a 6-hour x-ray post-procedure. Recurrence occurs in about 20% to 50% of cases, therefore simple aspiration is more effective in treating small as well as moderate spontaneous pneumothorax (Ebrahimi et al., 2014; Tschopp et al., 2015).

Insertion of an intercostal catheter in the case of primary spontaneous pneumothorax that does not improve with aspiration, significant secondary spontaneous pneumothorax (more than 50%), and tension pneumothorax. The insertion location is the same as the aspiration location. This method facilitates rapid re-expansion, thus eliminating the need for prolonged treatment. The use of impermeable drainage is better because it reduces the chances of developing pulmonary edema, which is more likely to occur when the lungs re-expand rapidly. Thoracostomy tubes currently use disposable polyethylene material with a metal trocar located in the center. Indications of accurate hose placement include observation of air bubbles during breathing and coughing, as well as increased level of water-covered fluid during inhalation. If the lungs fail to expand or if there is continuous air leakage for 72 hours after the thoracotomy tube is placed, alternative approaches such as thoracoscopy or thoracotomy should be considered for further therapy (Ebrahimi et al., 2014; Tschopp et al., 2015).

In this scenario, the first step is to conduct a primary survey as part of the management process. After ensuring the stability of the patient, supportive therapy can be initiated, including administering 3 liters of oxygen per minute, administering hydration therapy, ensuring bed rest, and closely monitoring vital signs. In addition, the patient underwent implantation of a Wireless Sensor Device (WSD), which resulted in improvement in the patient-reported dyspnea symptoms. The patient is hospitalized and receives symptomatic treatment, including Biocombin, a multivitamin administered in 1 ampoule every 24 hours in the form of drops. In addition, Ranitidine, a drug used to lower stomach acid production, is given at a dose of 50 mg every 12 hours intravenously. To reduce discomfort, Ketorolac is given intravenously at a dose of 30 mg every 8 hours, Nebu Combivent resp/24 hours/inhalation and Nebu Pulmicort resp/24 hours/inhalation to treat shortness of breath, Ambroxol 30 mg 3x1 tab to treat coughing up

phlegm, Dexamethasone 1 amp/12 hours/IV to treat inflammation, Ampicillin Sulbactam 1.5 gr/12 hours/IV as an antibiotic, Cefadroxil 500 mg 2x1 tab as antibiotic, Mefenamic Acid 500 mg 2x1 tab for pain relief.

Conclusion

Pneumothorax often arises in cases of cavitory tuberculosis or active tuberculosis, which leads to the development of secondary spontaneous pneumothorax. Patients with secondary spontaneous pneumothorax generally present with complaints of dyspnea and discomfort in the ipsilateral pleuritic chest. During the physical examination of the chest, observation shows reduced movement of the chest wall on the affected side. Chest percussion produces hyperpersonor sounds, which indicate an increase in air volume in the chest area. Palpation indicates a decrease in tactile fremitus, and auscultation indicates a weakening of the sound of breathing on the affected side. A chest X-ray can show avascular hyperlucence or pleural lines, which are white lines on the pleura that indicate a pneumothorax. In cases of pneumothorax secondary to previous pulmonary tuberculosis, the primary treatment involves the insertion of a chest tube, which has proven effective in relieving the patient's dyspnea symptoms.

References

- Amanda, A. P., & Wijayanti, O. (2015). Pneumotoraks pada Tuberkulosis Milier: Sebuah Laporan Kasus. *Indonesian Journal Of Chest*, 2(4), 191–194.
- Andres Giraldo Vallejo, F., Romero, R., Mejia, M., & Quijano, E. (2019). Primary Spontaneous Pneumothorax, a Clinical Challenge. In *Pneumothorax*. IntechOpen. <https://doi.org/10.5772/intechopen.83458>
- Daley, B. J. (2024). *Pneumothorax*. Emedicine.Medscape.Com. [emedicine.medscape.com](https://www.emedicine.medscape.com)
- Ebrahimi, A., Yousefifard, M., Kazemi, H. M., Rasouli, H. R., Asady, H., Jafari, A. M., & Hosseini, M. (2014). Diagnostic Accuracy of Chest Ultrasonography versus Chest Radiography for Identification of Pneumothorax: A Systematic Review and Meta-Analysis. *Tanaffos*, 13(4), 29–40.
- Franco, A. I., Arponen, S., Hermoso, F., & García, M.-J. (2019). Subcutaneous Emphysema, Pneumothorax and Pneumomediastinum as A Complication of An Asthma Attack. *Indian Journal of Radiology and Imaging*, 29(01), 77–80. https://doi.org/10.4103/ijri.IJRI_340_18
- Guyton, A. C., & Hall, J. E. (2007). *Buku Ajar Fisiologi Kedokteran*. EGC.
- Huan, N.-C., Sidhu, C., & Thomas, R. (2021). Pneumothorax. *Clinics in Chest Medicine*, 42(4), 711–727. <https://doi.org/10.1016/j.ccm.2021.08.007>
- Jayanti, L. (2018). *Faktor-faktor yang Mempengaruhi Kesintasan Pasien Stroke di Rumah Sakit Pusat Angkatan Darat Gatot Soebroto tahun 2014-2017*. Universitas Indonesia.
- Karmakar, S. (2022). Pneumothorax: A Concise Review and Surgical Perspective. In *Pleura - A Surgical Perspective*. IntechOpen. <https://doi.org/10.5772/intechopen.101049>
- Masengi, W. D., Loho, E., & Tubagus, V. (2016). Profil Hasil Pemeriksaan Foto Toraks Pada Pasien Pneumotoraks di Bagian/SMF Radiologi FK Unsrat RSUP Prof. Dr. RD Kandou Manado periode Januari 2015–Agustus 2016 . *E-CliniC*, 4(2). <https://doi.org/10.35790/ecl.v4i2.14397>
- Putri, P. P., & Kaniya, T. D. (2019). Evaluasi Radiologis Pneumotoraks Spontan Sekunder Pada Pasien dengan Tuberkulosis Paru Kasus Relaps. *Medical Profession Journal of Lampung*, 9(2), 359–365. <https://doi.org/10.53089/medula.v9i2.283>
- Setiati, S., Alwi, I., Sudoyo, A. W., K., M. S., Setiyohadi, B., & Syam, A. F. (2014). *Buku Ajar*

Ilmu Penyakit Dalam Jilid II (VI). Interna Publishing.

- Simamora, R. P. A., & Rasyidah. (2020). Laporan Kasus: Radiografi Thorax Pada Pasien Tb Paru dengan Pneumothorax Spontan Sekunder. *Majority 9.1*, 9(1), 141–145.
- Singh, A. S., Atam, V., & Das, L. (2014). Secondary Spontaneous Pneumothorax Complicating Miliary Tuberculosis in A Young Woman. *Case Reports*. <https://doi.org/10.1136/bcr-2013-201109>
- Tschopp, J.-M., Bintcliffe, O., Astoul, P., Canalis, E., Driesen, P., Janssen, J., Krasnik, M., Maskell, N., Van Schil, P., Tonia, T., Waller, D. A., Marquette, C.-H., & Cardillo, G. (2015). ERS task force statement: diagnosis and treatment of primary spontaneous pneumothorax. *European Respiratory Journal*, 46(2), 321–335. <https://doi.org/10.1183/09031936.00219214>