



## Article Review: Skin Diseases in Dromedary Camels

Hasanain A.J. Gharban<sup>1</sup> 

<sup>1</sup>Department of Biochemistry, Faculty of Life Sciences, Kebbi State University of Science and Technology, Aliero, Kebbi State, Nigeria

\*Corresponding Author: Hasanain A.J. Gharban

Email: [hghirban@uowasit.edu.ig](mailto:hghirban@uowasit.edu.ig)



### Article Info

#### Article history:

Received 6 May 2024

Received in revised from 9 June 2024

Accepted 24 June 2024

#### Keywords:

One Humped Camel

Cutaneous Diseases

Iraq

### Abstract

The dromedary camel (*Camelus dromedarius*) is a significant livestock species in several nations located in desert and semi-arid regions of Asia, Northern and Eastern Africa, South America, and the high highlands of the Andes. In Iraq, the FAO figures of 2014 indicate that there are around 65,000 camels, all of which belong to the species *Camelus dromedarius* and have a single hump. Camels are the primary source of sustenance for all Bedouin clans and villages in various ecological zones in Iraq. This dependence involves the usage of camel milk, meat, leather, and wool. Furthermore, camels have been used as beasts of burden, means of transportation, and mounts. Camels, typically grown in their native desert environment, experience significant stress due to the prolonged dry season. This stress makes them vulnerable to many illnesses and health issues. Historically, owing to little research on camel ailments, doctors believed that camels were immune to many disease-causing causes. Scientific evidence has shown that camels, like other livestock or maybe even more so, are vulnerable to the same disease-causing viruses that impact other animal species. Camels often suffer from illnesses that are challenging to manage because to their non-specific symptoms and similarity to diseases seen in other ruminant animals. Additionally, camels have some resistance to some infections. This research attempts to provide a concise description of the most frequently seen skin disorders in dromedary camels in Iraq.

## Introduction

For a considerable duration, there has been a mistaken belief that both one-humped and two-humped camels originate from a single wild species known as *Camelus ferus*. There were two primary justifications for this notion. Firstly, both one-humped and two-humped camels go through a two-humped embryonic phase. Secondly, the offspring resulting from the mating of dromedaries (one-humped camels) and bactrians (two-humped camels) are capable of reproducing. Recent osteological studies on the post cranial bones of dromedaries (*Camelus dromedarius*) and Bactrian camels (*Camelus bactrianus*) have shown that they originate from distinct species, as demonstrated by Wernery & Kaaden in 2002 and Kadim et al. in 2013.

Domain: Eukaryota, Kingdom: Animalia, Phylum: Chordata, Class: Mammalia, Order: Artiodactyla, Family: Camelidae, Tribe: Camelini, Genus: *Camelus*, Species: *C. dromedaries*

There is a significant level of ambiguity, making it difficult to get an accurate assessment of the present global camel population. Out of the 46 national entities reporting their camel population in the latest FAOSTAT database, only 50% of the data is officially given by national ministries. The remaining 50% is estimated by the FAO. This research seeks to provide a comprehensive analysis of the existing data on the global camel population and its demographic fluctuations (Faye, 2020). Camels engage in the process of regurgitation and re-chewing of their meal, which is known as rumination. Nevertheless, from a taxonomic perspective, they

are not officially classified as members of the Ruminantia group. The three anterior stomachs of the animal are referred to as compartments. The term "dromedary" originates from the Greek language and signifies "running". The Bactrian camel received its name from the Bactria area in South-West Asia (Skidmore et al., 1992). Camels serve several purposes, including being used as draught and riding animals, as well as for their meat, milk, skins, and wool. Comparative technical data indicates that the fat level of camel meat is much lower than that of beef. Nevertheless, the protein level is equivalent to that of beef. Research has shown that camel skins possess a remarkable tensile strength that is five times higher than that of cow hides. Currently, camel leather is being transformed into high-quality fashion clothing, supple leather wallets, handbags, and purses. Wool is a significant by-product of dromedaries in several nations that produce camels. The mean wool yield is 3.28 kg for males and 2.10 kg for females. The Bedouins manufacture carpets and tents from camel wool. Camel wool is renowned as one of the costliest natural animal fibers globally. It has similarities with cashmere in terms of both fiber diameter and texture. The Bactrian camel, among the Old-World camels (OWC), yields higher quality wool compared to the dromedary, as stated by Khomeiri et al. (2015).

Male Bactrian camels have the capacity to provide an impressive 10-16 kg of high-quality fiber. However, however, there is now less demand and enthusiasm for the camel wool sector. Nevertheless, there is a growing need for NWC fiber due to the fact that the vicuna is renowned for producing the most superior wool of all animals. The fascination with its fiber has prevented the extinction of this wonderful creature. It yields a mere 200 grams of wool annually. This is one of the rationales for scientists' engagement in cross-breeding NWC with OWC. A male dromedary and a female guanaco were successfully bred together in the United Arab Emirates (UAE), resulting in the first hybrid offspring (Wernery & Kaaden, 2002; Raziq, 2009).

Since the 1980s, the dromedary has had a resurgence in popularity, not only among scientists, but also in the nations where it is used for riding and transportation. The milk, leather, and flesh of the animal are all used, and it has also become a popular tourist attraction (Bornstein & Younan, 2013). The dromedary species is guaranteed a secure future, even in the face of competition from modern transportation and other domesticated animals. Furthermore, it poses no damage to domesticated animals or any endangered nature. Researchers have lately heightened their investigation into the dromedary and are now debating the existence of distinct dromedary "varieties" (Harris, 2021).

Estimates suggest that the global population of camels is around 19 million, with around 15 million found in Africa and 4 million in Asia (Berhe et al., 2017). Because of their physiological adaptations to thrive in tough desert conditions, they mostly inhabit semiarid and arid regions of Africa. The dromedary, which has one hump, constitutes 94% of the worldwide population of this species. However, the wild Bactrian variety, which has two humps, is in danger of becoming extinct (Chuluunbat et al., 2014). The camel population has declined in certain nations, including Libya and the Gulf States, due to the stagnation of nomadism caused by the presence of oil. Nevertheless, there has been a contrasting shift in the UAE in recent years, as the dromedary has seen a resurgence, leading to the rebirth of the ancient Bedouin practice of camel racing (Kishore et al., 2024).

The dromedary is able to live and carry out activities in the harsh desert environment because to its unique morphological and physiological features, which might be beneficial for humans (Qureshi et al., 2020). One additional benefit is that camels have a low vulnerability to infections, particularly viral diseases. However, bacterial illnesses have a more significant impact on them (Al-Hassani et al., 2018). The scarcity of publications on infectious illnesses

of camelids may be attributed to the camel's natural resilience to many disease-causing microbes and the overall lack of interest in studying the camel family. This lack of interest is evident in the limited number of publications on the topic, as noted by El-Gayown (1986) and Margan (1987).

### Camels in Iraq

Only *Camelus dromedarius* has domesticated in Iraq involving these types: (1) Al- Judiya that spread in the middle and south of Iraq characterized by large body making them used in transporting; (2) Al- Majaheem that found in small numbers characterized by black – dark brown color; (3) Al-Maghateer that found in 5%; (4) Al-Omaniya that found in 4%; (5) Al-Hurra is the less common type present about 1% in Iraqi; (6) Al-Khwar that spread in the north of Iraq and the land between Iraq and Syria characterized by their small size and low and small head light color and high production of milk (Al-Ani et al., 1990).

### Skin in camel

The skin is the body's biggest organ, responsible for protecting the body and regulating homeostasis. The skin plays a role in maintaining body temperature by providing insulation and facilitating heat dissipation via sweat. Skin abnormalities might arise from particular dermatological conditions or from the compromised overall health of the animal. The skin has a crucial role in diagnosing many instances of declining health, poor growth, and weakness, in addition to overall health condition (Klopries et al., 1995). The skin is composed of several components, including hair, hair follicles, sebaceous glands, and sweat glands. The immune system is a crucial defense mechanism in the body that serves as the interface between the body and the external environment. As a result, the skin is very susceptible to infection by many pathogens, as seen in figure (1). The skin consists of three layers: the epidermis, dermis, and subcutis. In normal animals, the skin has significant flexibility, which enables bodily mobility (Hirschman, 1998; Al-Hassan, 2020).

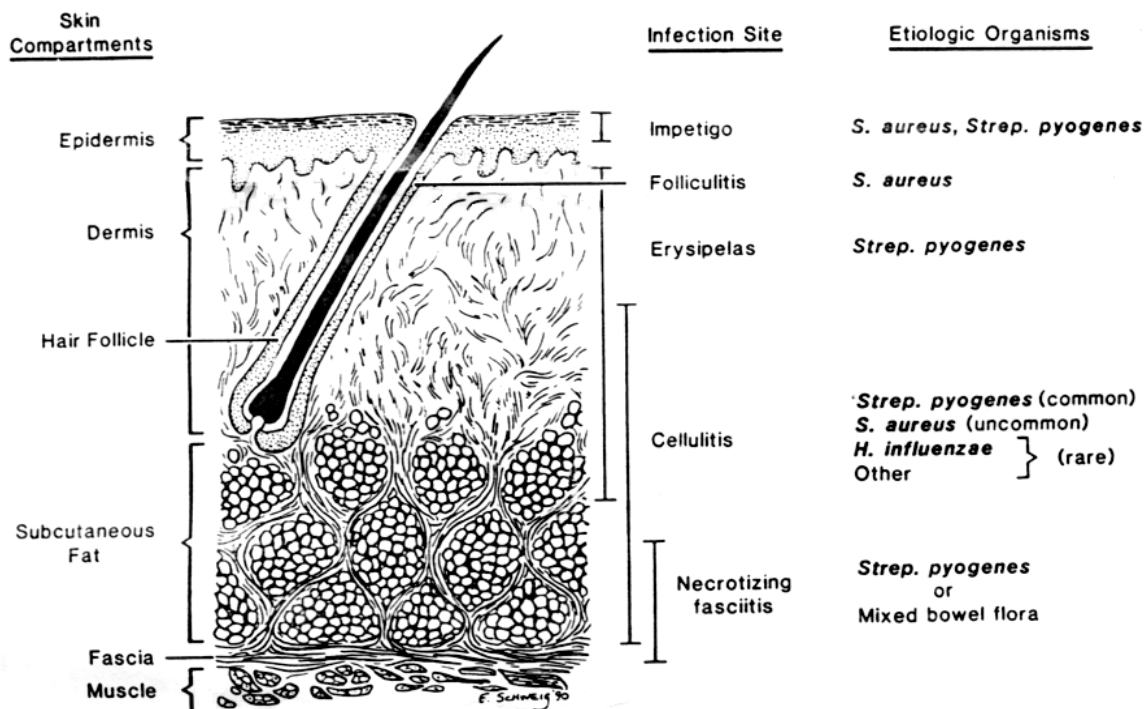


Figure 1. Cutaneous anatomy, sites of infection and infecting pathogens

The skin affection has divided into two types: (1) Primary infections emerge in the skin itself and caused by a pathogenic microorganism that is specific to the skin like dermatophytosis; (2) Secondary infections occur when there is a systemic infection, predisposing factor and /or allergic or metabolic disorders (Tuteja et al., 2013).

The most common important signs of skin diseases are: (a) Dermatitis is the inflammation of the skin can be produced by numerous agents, including external irritants, burns, allergens, trauma and infection (bacterial, viral, parasitic, or fungal). It can be associated with concurrent internal or systemic disease, and hereditary factors also may be involved. Allergies form an important group of etiologic factors, especially in small animals (Ayalew et al., 2015); (b) Pruritus (itching) is another manifestation of skin diseases in which unpleasant sensation of irritation within the skin provokes the desire to scratch. Pruritus is a sign and not a disease; it's commonly elicited in domestic animals by allergic diseases, ectoparasites, bacterial infections and idiopathic conditions (Bhagat et al., 2017).

### **Skin Diseases**

Skin affections may be sorted depending on the causative agents. *Staphylococcus* spp. infection is the most common infectious pathogen of skin. Virulence of *Staphylococcus* spp. for domestic animals is almost always multi-factorial, but interaction with animal hosts usually includes a few common steps. The organism enters through breaks in the skin barrier; such lesion can be initiated by sharp teeth of animals competing for feeding space. As the disease progresses, the skin becomes thickened, and layers of the epidermis may peel off (Devrajani et al., 2010).

Dermatophilosis is another important bacterial skin disease is dermatophilosis. The infection is ascribed to *Dermatophilus congolensis* is a typical epidemic in the humid tropics. Dermatophilosis occurs primarily in cattle, small ruminants, equidae, humans and certain non-domesticated species such as zebra and red deer, and transmitted to man by contact with infected animals (Osman et al., 2014).

Pseudotuberculosis is a chronic disease caused by *Corynebacterium pseudotuberculosis*, which characterized by abscessation of one or more subcutaneous palpable lymph nodes. Also, it sometimes causes pneumonia, hepatitis, mastitis, arthritis, orchitis and subcutaneous abscesses. Pseudotuberculosis is widespread in camel and the organism has been isolated from abscesses (Mubarak & Moussa, 2022).

Various fungal species can produce an infection in epidermis, as causing by dermatophytosis (ringworm) which is the commonest in camels (Shokri & Khosravi, 2011). With the exception of camel pox complex, a grave lack of information exists regarding viral diseases in camelids. Although all camelid species possess multiple physiological and anatomical similarities, and it is believed that they do not differ in their susceptibility to viruses, comparison of NWC with OWC is important to indicate any possible familial susceptibility. Only a few viruses appear to cause disease in camelids, including the camel pox, contagious ecthyma, and papillomatosis (Kandeel & Al-Mubarak, 2022).

Camel pox occurs in dromedary and Bactrian camel and has been, also, experimentally induced in NWC. The camel pox virus causes a proliferative skin disease that primarily affects younger animals. Camel may become infected with poxvirus through small abrasions of skin, by aerosol infection of the respiratory tract or mechanical transmission by biting arthropods (Dahiya et al., 2016).

Contagious Ecthyma (Orf) is caused by *Parapoxviruses* as a localized, vesiculo-pustular exanthema with a worldwide distribution. It is regarded as one of the most serious viral diseases

in camel, and it is very difficult to differentiate clinically from true camel pox. Camel contagious ecthyma occurs mainly in young animals up to 3 years of age (Khalafalla et al., 2015).

Papillomatosis (warts) are benign neoplastic growths of skin and mucous membranes, and are observed worldwide in humans and a variety of animals. They are caused by species-specific papillomaviruses that have been associated with development of squamous cell carcinomas. Although, cattle are more affected by warts than any other domestic animal species, it can affect camels and cause typical skin lesions (Hussain et al., 2012; Elfadl et al., 2016).

Camels, like other livestock, are exposed to and affected by a range of ectoparasites that may directly or indirectly cause a great diversity of health problems. Some ectoparasites play a significant role in many disorders. For example, some biting insects act as vectors for disease agents such as *Trypanosoma evansi*, and the mite *Sarcoptes scabiei* is the cause of sarcoptic mange (Momenah, 2014).

### **Mange**

Sarcoptic mange is regarded to one of the most prevalent and serious camel diseases and second in importance to all disorders in dromedary camels after trypanosomosis. It a chronic debilitating condition with high morbidity and low mortality.

Psoroptic mange spends their entire life on the skin, feeding superficially. They reportedly infest camel but less commonly found than *S. scabiei*

Chorioptic mange occurs with infestation of *Chorioptes* is most probably rare in camels. It has been reported on a Bactrian camel.

Demodectic mange occurs due to burrowing mite of *Demodex* genus in the hair follicles and sebaceous glands of skin. It is a cigar- shaped, elongated mite that transmitted from dam to offspring during nursing. *Demodex* is found in all domestic mammals, worldwide, and most species are named according to their hosts. The most significant sequel to infestation is the damage to the hides, causing economic loss (Ahmed et al., 2020).

### ***Infestations with Ticks***

Because of their large size and pesky habits, ticks have been recognized for centuries (Gharbi et al., 2013). The pathogenesis is attributable to these parasites appears in several ways:

**Anemia:** Blood loss in heavy infestation can be considerable as much as 200 pounds of blood can be lost from a single large host in one season (Al-Gharban & Al-Tae, 2016; Al-Abedi et al., 2020).

**Inflammation:** Swelling ulcerations and itching can result from a tick bite. These reactions are often caused by pieces of mouthparts remaining in a wound after a tick is forcibly removed, but constituents of tick saliva and secondary infection by bacteria probably are also involved (Wajid, 2017).

A condition known as tick paralysis is common in humans, dogs, cattle and other mammals when they are bitten near the base of their skull. This paralysis seems to result from toxic secretions and is quickly reversed when the parasite is removed (Gameel, 2021). Infestation of an ear canal by ticks causes a serious irritation to the host, sometimes accompanied by severe infections (Cakabay et al., 2016).

In addition to transmitting common pyogenic infections, ticks are important vectors of protozoal, bacterial, viral and rickettsial diseases in many animal species. However, their vector

role appears to be much less important in camels than in other livestock. Being blood-feeders, ticks may cause debility and anemia in camels and other animals (Al-Rawashdeh et al., 2000).

Camels may suffer from both biting and sucking lice and both may be found on the same individual. Biting lice have a blunt broad head that is distinctly different from the elongated mouthparts of the sucking lice (Barbieri et al., 2019). Some flies as adults are external parasites, while some parasitize on tissues of the hosts as larvae, causing myiasis. Many members of this order are also important vectors of pathogens (Jalali et al., 2016; Getahun et al., 2022).

Cutaneous tumors are the most frequently diagnosed neoplastic disorders in domestic animals, in part because they can be identified easily and in other part because the constant exposure of skin to external environment predisposes this organ to neoplastic transformation. Chemical carcinogens, ionizing radiations, and viruses have been implicated, but hormonal and genetic factors may also play a role in development of cutaneous neoplasm (Al-Sobayil & El-Amir, 2013; Elmaghraby et al., 2023). Many anomalies can affect the keratinized tissue, and some are associated with hereditary hypotrichosis, while others are associated with systemic metabolic derangements. Other forms include seborrheic syndromes, Cutaneous ichthyosis hyperkeratosis on the skin surface (Cebra, 2014; Lakritz, 2022).

### **Photosensitization**

In photosensitization, highly pigmented skin is hyperactive to sunlight. Molecules of photosensitization agents in the skin are energized by light, when the molecules return to the less energized state, the released energy is transferred to receptor molecule that quickly initiate chemical reaction in components of the skin. Tissue energy probably results from the production of reactive oxygen intermediates or from alterations in cell membrane permeability. Photosensitization differs from sunburn in which lightly pigmented skin slowly becomes inflamed after exposure to ultraviolet rays (Khater et al., 2016; Mohammed et al., 2023).

A skin affection characterized by multiple plaque-like eruptions that are formed by localized edema in the dermis and that often develop and disappear suddenly. It occurs in all domestic animals but most often in horses. Allergic urticaria may be exogenous or endogenous (Ehlayel & Bener, 2018).

The definitive diagnosis of various skin diseases requires a detailed history, physical examination and appropriate diagnostic tests. The careful dermatologic history is critical to interpreting the physical examination findings and choosing appropriate diagnostic tests. The following information should be obtained: (1) Information about prior illness, vaccinations, husbandry, changes in attitude or diet, or travel within the past 6-12 months; (2) Primary complaint; (3) Length of time in which the problem has been present; (4) Age at which the affection started; (5) Breed and sex; (6) Presence and severity of pruritus, epidermitis and hair loss; (7) How the disease started and its progression; (8) Type of the lesion in which: a) Distribution on the body; b) Size, shape and frequency; c) Consistency; d) Lesion types (macule, papule, nodule, plaque, mass, vesicle, pustule, scale, crust, erosion, excoriation, laceration, ulcer, scar, fissure, sweating, necrosis, or keratosis; e) Skin temperature and color; f) Subcutis edema, masses, or others; g) Superficial lymphnodes; h) Mucous membrane; (9) Evidence of seasonality; Area on the body the problem was first noticed; 10) Any previous treatment and their responses; 11) Frequency of bathing and date of the last one; 12) Presence of ectoparasites; 13) Other animals in contact; 14) Environment of the animals (housing) (Ngeiywa et al., 1992; Alhaj et al., 2019).

## Physical examination

A complete physical examination should be always performed. Many skin diseases are manifestations of systemic diseases, ex. hypothyroidism and systemic lupus erythematosus. A good dermatologic examination requires very close inspection of the entire hair coat and skin under strong lighting; flashlights may be necessary to examine the skin of large animals. Gross lesion can be described as focal, multifocal, or diffused in distribution, followed by a description of the affected region (Tefera, 2004; Talotta & Robertson, 2021).

## Appropriate diagnostic tests

Skin scraping: is a part of basic database for all skin diseases. There are 2 types of skin scrapings, superficial and deep. Superficial skin scrapings don't cause a capillary bleeding and provide information about surface of epidermis. Deep skin scrapings collect material from within the hair follicle capillary bleeding indicates that the sampling was deep enough. Skin scrapings are used primarily to determine the presence or absence of mites (Ganguly et al., 2017).

Combing of the hair coat is referred to as flea combing. This technique is useful for collecting large amounts of skin debris and trapping cutaneous parasites, particularly, fleas, ticks, lice and some mites (Ansari-Renani et al., 2010). Microscopic examination of hair shafts can be used to look for evidence of self-trauma, dermatophyte infections, dysplastic hairs, and sometimes genetic diseases of hair coat (Wiam et al., 2015).

Cutaneous and auricular cytology is helpful in identifying the bacterial, fungal, and possibly neoplastic skin diseases. At least four to six impression smears should be made and several slides should be saved for examination (Ahmadi et al., 2005). Dermatophyte infections are best identified with a fungal culture on either *Dermatophyte* Test Medium (DTM) or on Modified Sabouraud Dextrose Agar (SDA). In large animals; hairs should be gently wiped with alcohol before collecting to minimize contaminant growth (Bokhari, 2010).

Intact pustules can be cultured by aspirating pustule contents with sterile needle and swabbing lesion with a sterile culture swab (Rahman et al., 2009). Skin biopsies are indicated in any case that appears severe, unusual, or doesn't respond to appropriate therapy. Lesions should not be scrubbed before biopsy because surface pathology is important in the diagnosis of many skin diseases (Sobayil & El-Amir, 2013).

In most dermatologic cases, these tests are not helpful because they don't help to make a definitive diagnosis. If systemic signs of an illness are present, the complete blood count, serum chemistry panel and urinalysis may be helpful in identifying the etiology (El-Deeb & Buczinski, 2015; Faye & Bengoumi, 2018). A positive intradermal skin test reaction indicates past exposure to a particular allergen. Intradermal skin testing is recommended for animals, in which, immunotherapy is indicated due to the severity or duration of allergic signs (Jibril et al., 2018).

*In vitro* diagnosis test: ELISA tests are an alternative to intradermal skin testing. Although *in vitro* tests are considered less reliable because of the large number of false positive reactions, most complications in interpretation are the result of poor patient selection (Khalafalla et al., 2020).

## ORCID

Hasanain A.J. Gharban  <https://orcid.org/0000-0002-6438-1450>

## References

- Ahmadi, M. R., Nazifi, S., Ghaisari, H. R., & Radmehr, M. (2005). Evaluation of reproductive cycle with cervical and uterine cytology in Iranian dromedary camels. *Comparative Clinical Pathology*, *14*, 48-51.
- Ahmed, M. A., Elmahallawy, E. K., Gareh, A., Abdelbaset, A. E., El-Gohary, F. A., Elhawary, N. M., & Abushahba, M. F. (2020). Epidemiological and histopathological investigation of sarcoptic mange in camels in Egypt. *Animals*, *10*(9), 1485. <https://doi.org/10.3390/ani10091485>
- Al-Abedi, G. J., Sray, A. H., Hussein, A. J., & Gharban, H. A. (2020). Detection and Bloody Profiles Evaluation of Naturally Infected Camels with Subclinical Trypanosoma evansi, Iraq. *Annals of Tropical Medicine and Public Health*, *23*, 232-243.
- Al-Ani, F. K. Al-Bassam, L.S. & Al-Salahi, K.A. (1990). Epidemiological study of dermatomycosis due to *Trichophyton schoenleinii* in camels in Iraq. *Bull. Anim. Hlth. Prod. Afi.* *43*: 87-92.
- Al-Gharban, H. A., & Al-Tae, H. S. (2016). Seroclinical diagnosis of Anaplasma marginale bacteria in carrier arabian one-humped camels. *Basrah J Vet Res*, *15*, 346-359.
- Alhaj, O. A., Faye, B., & Agrawal, R. P. (Eds.). (2019). *Handbook of research on health and environmental benefits of camel products*. IGI Global.
- Al-Hassan, A. A. (2020). Gelatin from camel skins: Extraction and characterizations. *Food Hydrocolloids*, *101*, 105457. <https://doi.org/10.1016/j.foodhyd.2019.105457>
- Al-Hassani, M.K.A., Al-Gharban, H.A.J., & Manher, L.F. (2018). Application of Three Diagnostic Serologic Techniques to Detect of Dromedary Camel's Brucellosis. *Al-Qadisiyah journal For pure science*, *23* (2), 61-74.
- Al-Rawashdeh, O. F., Al-Ani, F. K., Sharrif, L. A., Al-Qudah, K. M., Al-Hami, Y., & Frank, N. (2000). A survey of camel (*Camelus dromedarius*) diseases in Jordan. *Journal of Zoo and Wildlife Medicine*, *31*(3), 335-338. <https://doi.org/10.1638/1042-7260>
- Al-Sobayil, F. A., & El-Amir, Y. O. (2013). Throughout pathological study on skin, subcutaneous and mucosal neoplasia of the dromedary camel. *Braz J Vet Pathol*, *6*(2), 48 – 55.
- Ansari-Renani, H. R., Salehi, M., Ebadi, Z., & Moradi, S. (2010). Identification of hair follicle characteristics and activity of one and two humped camels. *Small Ruminant Research*, *90*(1-3), 64-70. <https://doi.org/10.1016/j.smallrumres.2010.01.004>
- Ayalew, Y., Assefa, A., Mekonen, N., Belete, S., & Ayisheshim, A. (2015). A review on camel dermatophilosis. *Adv Biol Rev*, *9*, 363-372.
- Barbieri, R., Drancourt, M., & Raoult, D. (2019). Plague, camels, and lice. *Proceedings of the National Academy of Sciences*, *116*(16), 7620-7621.
- Berhe, T., Seifu, E., Ipsen, R., Kurtu, M. Y., & Hansen, E. B. (2017). Processing challenges and opportunities of camel dairy products. *International journal of food science*, *2017*, 1-8.

- Bhagat, R., Sheikh, A. A., Dar, R. R., Dogra, P., & Maibam, U. (2017). Resolving a clinical case of sarcoptic mange infestation in a dromedary camel. *Pharma Innov. J*, 6, 217-219.
- Bokhari, F. M. (2010). Implications of fungal infections and mycotoxins in camel diseases in Saudi Arabia. *Saudi Journal of Biological Sciences*, 17(1), 73-81.
- Bornstein, S., & Younan, M. (2013). Significant veterinary research on the dromedary camels of Kenya: past and present. *Bornstein/ Journal of Camelid Science*, 6, 1-48
- Cakabay, T., Gokdogan, O., & Kocyigit, M. (2016). Human otoacariasis: Demographic and clinical outcomes in patients with ear-canal ticks and a review of literature. *Journal of Otolaryngology*, 11(3), 111-117.
- Cebra, C. (2014). *Disorders of the skin* (pp. 379-391). Elsevier.
- Chuluunbat, B., Charruau, P., Silbermayr, K., Khorloojav, T., & Burger, P. A. (2014). Genetic diversity and population structure of Mongolian domestic Bactrian camels (*Camelus bactrianus*). *Animal genetics*, 45(4), 550-558.
- Dahiya, S. S., Kumar, S., Mehta, S. C., Narnaware, S. D., Singh, R., & Tuteja, F. C. (2016). Camel pox: A brief review on its epidemiology, current status and challenges. *Acta Tropica*, 158, 32-38. <https://doi.org/10.1016/j.actatropica.2016.02.014>
- Devrajani, K., Abubakar, M., Fazlani, S. A., Shahid, F., Ourban, A. S., & Imran, R. (2010). Occurrence and prevalence of bacterial species as identified from camel wound. *Inter. J. Agro Vet. Med. Sci*, 4(4), 96-104.
- Ehlayel, M., & Bener, A. (2018, September). Camel's milk allergy. In *Allergy & Asthma Proceedings* (Vol. 39, No. 5).
- El-Deeb, W. M., & Buczinski, S. (2015). The diagnostic and prognostic importance of oxidative stress biomarkers and acute phase proteins in urinary tract infection (UTI) in camels. *PeerJ*, 3, e1363.
- Elfadl, A. K., Jäger, K., Schoon, H. A., & Gameel, A. A. (2016). Frequency, pathology and electron microscopy of dromedary camel viral fibro-papilloma in Sudan.
- Elmaghraby, I., El-Mashad, A. B., Moustafa, S., & Amin, A. (2023). Pathological and immunohistochemical studies on skin and subcutaneous neoplasia in Arabian Camels (*Camelus dromedarius*). *Kafrelsheikh Veterinary Medical Journal*, 21(1), 4-11. <https://doi.org/10.21608/KVMJ.2023.210014.1034>
- Faye, B. (2020). How many large camelids in the world? A synthetic analysis of the world camel demographic changes. *Pastoralism*, 10(1), 1-10.
- Faye, B., & Bengoumi, M. (2018). *Camel clinical biochemistry and hematology* (pp. 173-216). Cham (Switzerland): Springer.
- Gameel, A. A. (2021). Tick Infestation. In *Infectious Diseases of Dromedary Camels: A Concise Guide* (pp. 235-238). Cham: Springer International Publishing.
- Ganguly, S., Para, P. A., & Praveen, P. K. (2017). Dermatophyte examination of skin scrapings collected from a camel: a case study. *Int. J. Curr. Microbiol. Appl. Sci*, 6(2), 1731-4.
- Getahun, M. N., Villinger, J., Bargul, J. L., Muema, J. M., Orone, A., Ngiela, J., & Masiga, D. K. (2022). Molecular characterization of pathogenic African trypanosomes in biting flies and camels in surra-endemic areas outside the tsetse fly belt in Kenya.

*International Journal of Tropical Insect Science*, 42(6), 3729-3745.  
<https://doi.org/10.1007/s42690-022-00896-2>

- Gharbi, M., Moussi, N., Jedidi, M., Mhadhbi, M., Sassi, L., & Darghouth, M. A. (2013). Population dynamics of ticks infesting the one-humped camel (*Camelus dromedarius*) in central Tunisia. *Ticks and tick-borne diseases*, 4(6), 488-491.  
<https://doi.org/10.1016/j.ttbdis.2013.06.004>
- Harris, D. R. (2021). Domesticatory relationships of people, plants and animals. In *Redefining nature* (pp. 437-463). Routledge.
- Hirschman, E. C. (1998). When expert consumers interpret textual products: applying reader-response theory to television programs. *Consumption, Markets and Culture*, 2(3), 259-309.
- Hussain, M., G Habasha, F., & A Hasso, S. (2012). Papillomatosis in Iraqi camels. *AL-Qadisiyah Journal of Veterinary Medicine Sciences*, 11(1), 70-74.
- Jalali, M. H. R., Dehghan, S., Haji, A., & Ebrahimi, M. (2016). Myiasis caused by *Cephalopina titillator* (Diptera: Oestridae) in camels (*Camelus dromedarius*) of semi-arid areas in Iran: distribution and associated risk factors. *Comparative Clinical Pathology*, 25, 677-680. <https://doi.org/10.1007/s00580-016-2246-9>
- Jibril, Y., Mamo, G., Issa, A., Zewude, A., & Ameni, G. (2018). Appraisal of interpretation criteria for the single intra-dermal comparative cervical tuberculin test for the diagnosis of tuberculosis in dromedary camels in Ethiopia. *Tropical animal health and production*, 50, 1665-1670. <https://doi.org/10.1007/s11250-018-1610-y>
- Kadim, I. T., Mahgoub, O., Al-Marzooqi, W., Khalaf, S. K., & Raiymbek, G. (2013). Composition, quality and health aspects of the dromedary (*Camelus dromedarius*) and bactrian (*Camelus bactrianus*) camel meats: a review. *Journal of Agricultural and Marine Sciences [JAMS]*, 18, 7-24.
- Kandeel, M., & Al-Mubarak, A. I. (2022). Camel viral diseases: current diagnostic, therapeutic, and preventive strategies. *Frontiers in Veterinary Science*, 9, 915475.
- Khalafalla, A. I., El-Sabagh, I. M., Al-Busada, K. A., Al-Mubarak, A. I., & Ali, Y. H. (2015). Phylogenetic analysis of eight sudanese camel contagious ecthyma viruses based on B2L gene sequence. *Virology Journal*, 12, 1-9. <https://doi.org/10.1186/s12985-015-0348-7>
- Khalafalla, A. I., Rashid, J., Khan, R. A., Alamin, K. M., Benkhelil, A., De Massis, F., & Al Muhairi, S. S. (2020). Preliminary comparative assessment of brucellergene skin test for diagnosis of brucellosis in dromedary camels (*Camelus dromedarius*). *Vector-Borne and Zoonotic Diseases*, 20(6), 412-417. <https://doi.org/10.1089/vbz.2019.2537>
- Khater, H., Hendawy, N., Govindarajan, M., Murugan, K., & Benelli, G. (2016). Photosensitizers in the fight against ticks: safranin as a novel photodynamic fluorescent acaricide to control the camel tick *Hyalomma dromedarii* (Ixodidae). *Parasitology Research*, 115, 3747-3758.
- Khomeiri, M., & Yam, B. A. Z. (2015). Introduction to Camel origin, history, raising, characteristics, and wool, hair, and skin: a review. *Research Journal of Agricultural and Environmental Management*, 4, 496-508.

- Kishore, A., Pal, B., & Sarkar, P. (2024). Camelids for Sustainability: A Socio-Economic Perspective. *Asian Journal of Environment & Ecology*, 23(1), 53-72.
- Klopries, M., Wernery, U., & Karden, O. R. (1995). Characterization of the camel skin cell line Dubca. *British Veterinary Journal*, 151(5), 555-565.
- Lakritz, J. (2022). Congenital/Hereditary Conditions. *Medicine and Surgery of Camelids*, 560-589.
- Mohammed, S. H., Baz, M. M., Ibrahim, M., Radwan, I. T., Selim, A., Dawood, A. F. D., & Khater, H. F. (2023). Acaricide resistance and novel photosensitizing approach as alternative acaricides against the camel tick, *Hyalomma dromedarii*. *Photochemical & Photobiological Sciences*, 22(1), 87-101. <https://doi.org/10.1007/s43630-022-00301-4>
- Momenah, M. A. (2014). Some blood parameters of one humped she camels (*Camelus dromedaries*) in response to parasitic infection. *Life Science Journal*, 11(5), 118-123.
- Mubarak, A., & Moussa, I. M. (2022). Sero-diagnosis of *Corynebacterium pseudotuberculosis* affecting camels using recombinant phospholipase D (rPLD) and anti-camels IgY-conjugate. *Journal of King Saud University-Science*, 34(8), 102344. <https://doi.org/10.1016/j.jksus.2022.102344>
- Ngeiywa, J. K. J. (1992). *Clinical and pathological investigations on camel skin diseases in some camel rich districts of Northern Kenya* (Doctoral dissertation).
- Osman, S. A. (2014). Camel dermatophilosis: Clinical signs and treatment outcomes. *Journal of camel Practice and Research*, 21(2), 199-204. <https://doi.org/10.5958/2277-8934.2014.00034.4>
- Qureshi, A. S., Rehan, S., Usman, M., Hayat, K., Umar, Z., & Sarfraz, A. (2020). Quantitative evaluation of age-related anatomical characteristics of selected digestive organs of dromedary camel. *Pakistan Veterinary Journal*, 40(2).
- Rahman, I. A., Dirar, H. A., & Osman, M. A. (2009). Microbiological and biochemical changes and sensory evaluation of camel milk fermented by selected bacterial starter cultures. *African Journal of Food Science*, 3(12), 398-405.
- Raziq, A. (2009). Portrayal of camelids in pastoral economy of north-eastern herders of Baluchistan. *PhD Diss., Deptt. Livestock Management, Univ. Agri Faisalabad, Pakistan*.
- Shokri, H., & Khosravi, A. R. (2011). Fungal flora isolated from the skin of healthy dromedary camels (*Camelus dromedaries*). *Int. J. Vet. Res*, 5(2), 109-112.
- Skidmore, J., Allen, W. R., Cooper, M. J., Chaudhry, M. A., Billah, M., & Billah, A. M. (1992). The recovery and transfer of embryos in the dromedary camel: results of preliminary experiments.
- Talotta, R., & Robertson, E. S. (2021). Antiphospholipid antibodies and risk of post-COVID-19 vaccination thrombophilia: The straw that breaks the camel's back?. *Cytokine & growth factor reviews*, 60, 52-60. <https://doi.org/10.1016/j.cytogfr.2021.05.001>
- Tefera, M. (2004). Observations on the clinical examination of the camel (*Camelus dromedarius*) in the field. *Tropical animal health and production*, 36, 435-449.
- Tuteja, F. C., Patil, N. V., Nagarajan, G., Narnaware, S. D., Dahiya, S. S., Singh, R. K., & Singh, S. (2013). Camel Dermal Mycoses: A Diagnostic Pictorial.

- Wajid, S. J. (2017). Dermatitis of camels (Camelus dromedaries) due to Tick infestation at abattoir of Sammawah in Iraq. *IOSR J. Agric. Vet. Sci*, 10(11), 12-15.
- Wernery, U. & Kaaden, O.R. (2002). Infectious diseases in camelids, 2<sup>nd</sup> revised and enlarged edition. *Blackwell Wissenschafts-Verlag GmbH Kurfirstendamm 57,10707 Berlin*
- Wiam, I. M., Sonfada, M. L., Yahaya, A., & Umar, A. A. (2015). Morphometric study of the skin in different anatomical regions of the camel (*Camelus dromedarius*). *Proceedings of International Camel Conference*, 17-21.